

Bilateral Krukenberg Tumor

Rupali Bargotra, Priya Gupta, Priynaka Mattoo*, Anshuman Sharma**, Anuradha**

Abstract

Krukenberg tumours are rare ovarian metastasis but responsible for most frequent diagnostic confusion with primary ovarian tumours. We hereby, present an isolated case of a 40 years old female who presented with fullness of lower abdomen diagnosed as bilateral Krukenberg Tumor on ultrasound and confirmed by histopathology.

Key Words

Krukenberg Tumour, Ovary, Signet Ring Cells

Introduction

Krukenberg tumours are rare ovarian metastasis but responsible for most frequent diagnostic confusion with primary ovarian tumours (1). They are often bilateral (over 80%), consistent with their metastatic nature. They were first described by Friedrich E Krukenberg a German pathologist in 1896. Krukenberg tumour refers to a "signet-ring" subtype of metastatic adenocarcinoma to the ovary. Novak and Gray advanced 3 criteria for Krukenberg tumour .

1. Cancer in the ovary
2. Presence of mucin producing signet ring cells
3. Ovarian stromal sarcomatoid proliferation (2)

Case Report

A 40 years old female presented with fullness of lower abdomen. Ultrasound revealed bilateral large well defined mass lesions with heterogeneous solid and cystic components in both uterine adnexa. In addition, there was gross ascites. Possibility of bilateral malignant ovarian tumours was suggested. Serum levels of CA-125 were

raised (140 U/ml) Patient underwent surgery for removal of both ovarian masses. On gross examination the ovarian tumours measured 15x9x10 cms and 17x11x7.5cm in size respectively. Both ovarian tumours showed bosselated outer surface with one ovary showing presence of few cysts on the surface. Cut surface was solid, firm, grey white and lobulated with one of the ovaries showing few cysts filled with serous fluid.

Microscopic examination of multiple sections from both the ovaries showed tumour cells arranged in clusters, tubules and small glands as well as individually infiltrating the densely cellular to oedematous stroma. The tumour cells had high nucleo cytoplasmic ratio, pleomorphic nuclei and moderate to abundant cytoplasm. Many signet ring cells were seen and their cytoplasm varied from pale, vacuolated to eosinophilic and granular. PAS stain for mucin was positive.(Fig.1-3)

Discussion

Krukenberg tumour is a metastatic signet ring cell

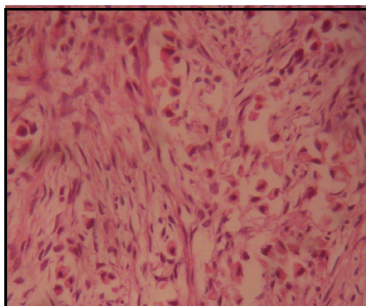
From the Department of Pathology, Radiology**, Govt Medical College Jammu and Consultant Radiologist*, J&K-India

Correspondence to : Dr . Rupali Bargotra, Assistant Professor, Post Graduate Department of Pathology, GMC Jammu.

Fig 1. Photograph of Bilateral Ovarian Tumours with Bosselated Outer Surface

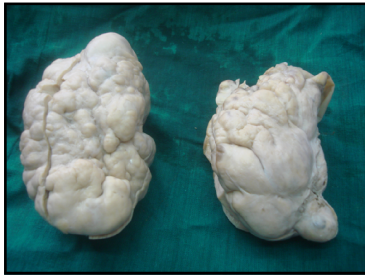

Fig 2. Photomicrograph Showing Tumour Cells Including Signet Ring cells (H&E, 40X)

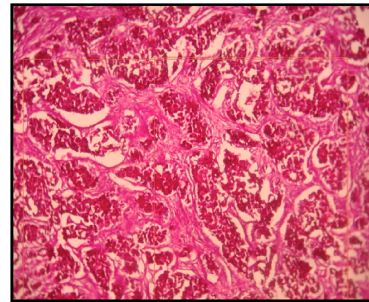


adenocarcinoma accounting for 1% to 2% of all ovarian tumours (3). Stomach is the primary site in most Krukenberg tumours. Carcinomas of colon, appendix and breast are the next common primary sites.

Patients with Krukenberg tumours tend to be young with an average age of 45 years and usually present with symptoms related to ovarian involvement such as abdominal pain and distension (4). Ascitis is usually present in 50% of cases (4).

The microscopic spectrum of Krukenberg tumour is very broad and tubules, glands and cysts are often present. Moreover the microscopic examination shows a great variation from case to case and also within the individual neoplasm. The cellularity of the stroma varies from densely cellular to paucicellular and the paucicellular areas ranging from oedematous to mucoid. Signet ring cells are seen in most neoplasms but are often absent or inconspicuous in significant areas. The signet ring cells vary widely in their arrangement, growing singly, in clusters, pseudo tubular arrays or as lining of true tubules. Small glands and tubules are common, often resembling microcysts (when the lining is flattened) or sertoli tubules

Fig 3. Photomicrograph Showing Mucin Positive Signet Ring Cells. (PAS with diastase, 10X)



(5). Although the entity of primary Krukenberg tumour cannot be denied, all women with typical Krukenberg tumours should be considered as having metastatic carcinoma until proved otherwise(6). The prognosis of patients with Krukenberg tumour is extremely poor with average survival time between 3 to 10 months. Only 10% of patients survive more than 2 years after diagnosis (7).

Conclusion

It is important to be familiar with diagnostic histopathological features of Krukenberg tumour for correct diagnosis and prevention of tumour misclassification.

References

1. Mardi K, Kaushal V, Kaur N. Tubular Krukenberg Tumour with an Occult Primary. *Online J Health Allied Scs* 2011; (10)1: 18
2. Novak C, Gray LA "Krukenberg tumor of ovary: Clinical and pathological study of four cases". *Surgery Gynaecology & Obstetrics* 1938;66(1):157-67
3. Mates IN, Iosif C, Banceanu G, Ionescu M, Peltecu G, Dinu D, Constantin A, Hoara P, Mitruce C, Constantinou S, Features of Krukenberg type tumours - clinical study and review. *Chirurgia* 2008; 103(1): 23-28
4. Al Agha OM, Nicastru AD. An in-depth look at Krukenberg tumor an overview. *Arch Pathol Lab Med* 2006, BO(11): 1725 - 1730
5. Kisyokawa T, Young RH, Scully RE. Krukenberg tumors of the ovary: a clinicopathological analysis of 120 cases with emphasis on their variable pathologic manifestations. *Am J Surg Pathol* 2006; 30(3): 277-99
6. Holtz F, Hart WR. Krukenberg tumors of the ovary: a clinicopathological analysis of 27 cases. *Cancer* 1982; 50: 2438-47
7. Das S, Sahu D, Wani M, Reddy PK. A curious discourse of Krukerberg tumor. A case report. *J Gastrointest Oncol* 2014; 5(6): E 117 - E 120